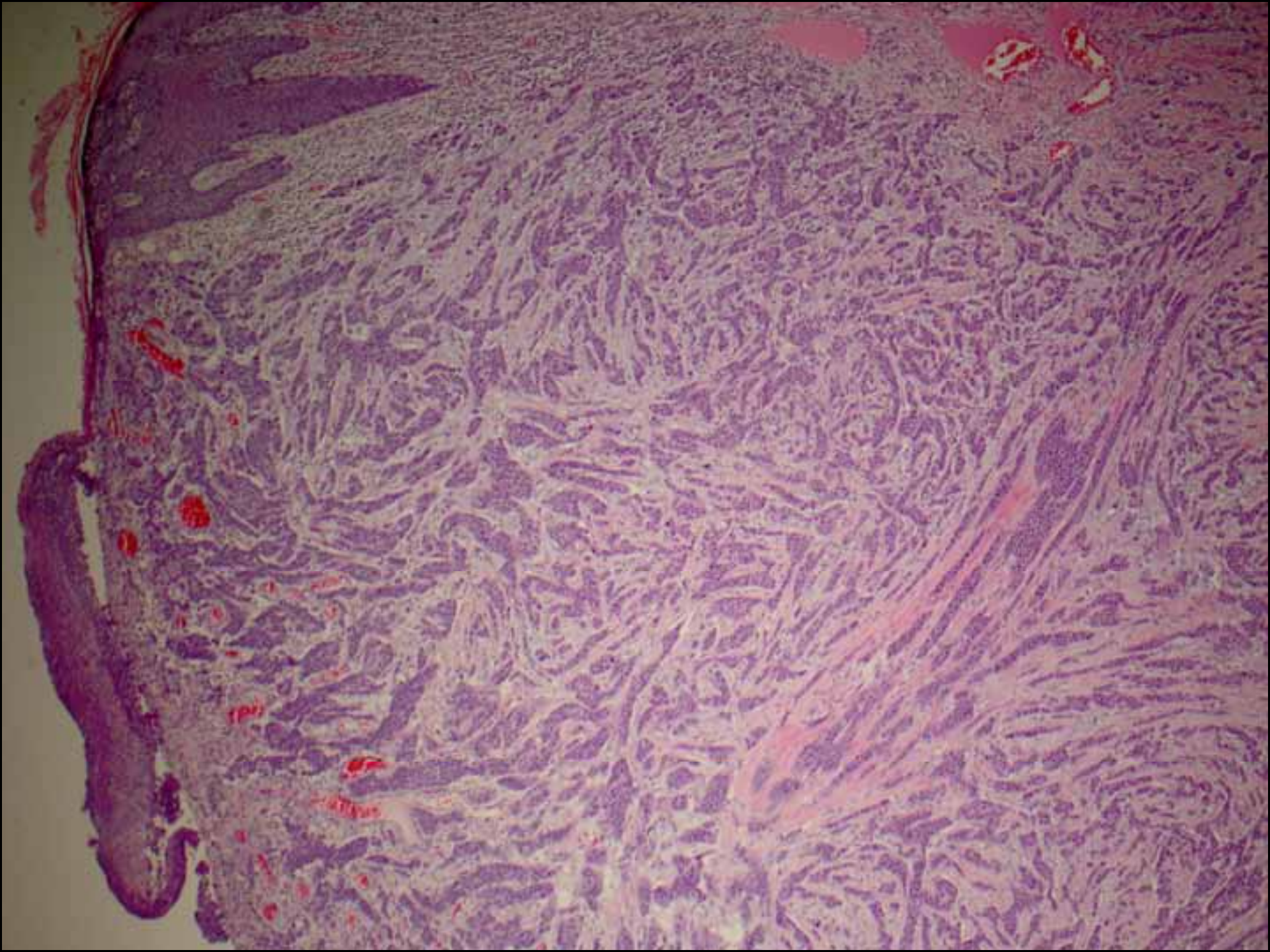
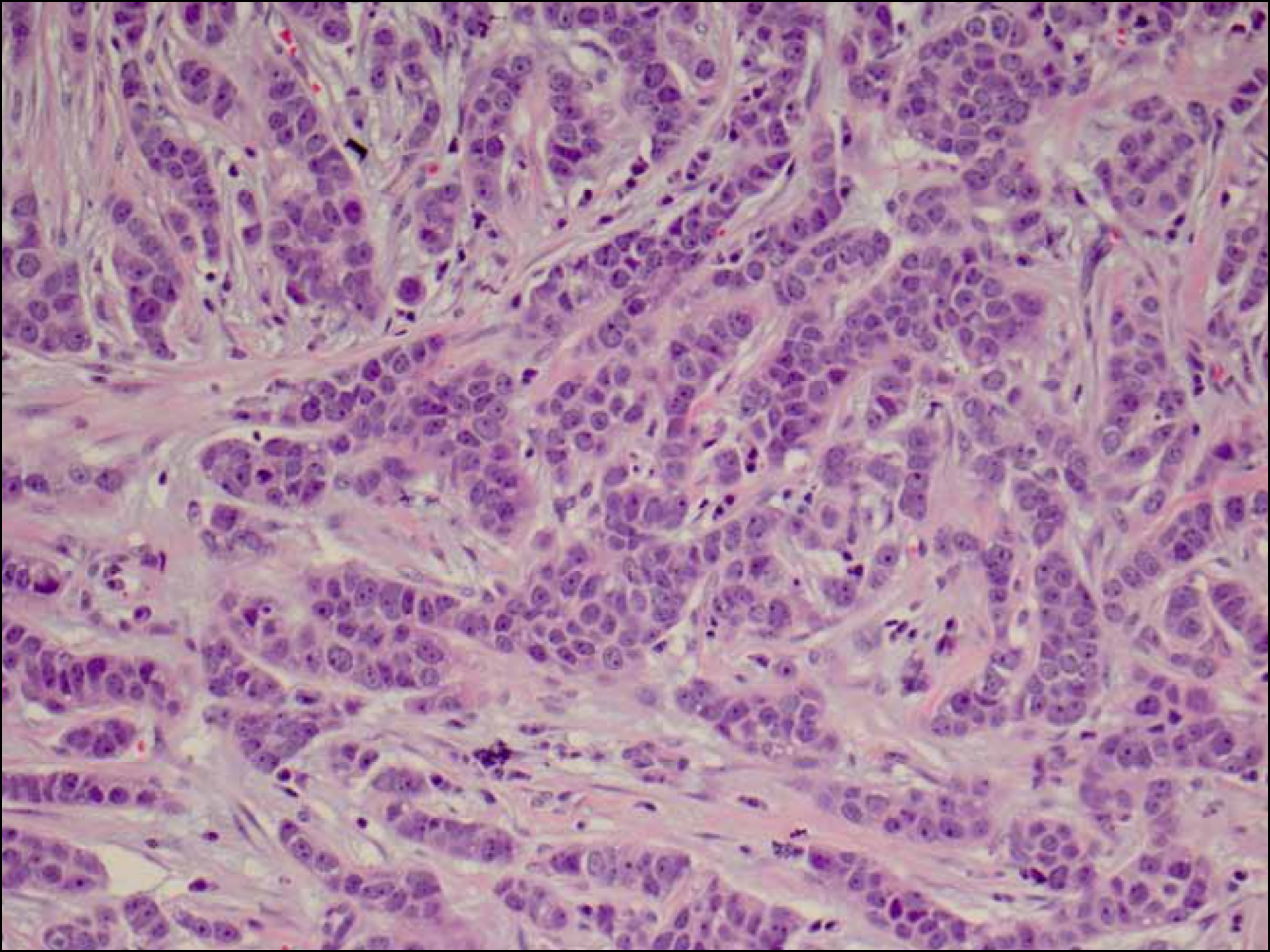
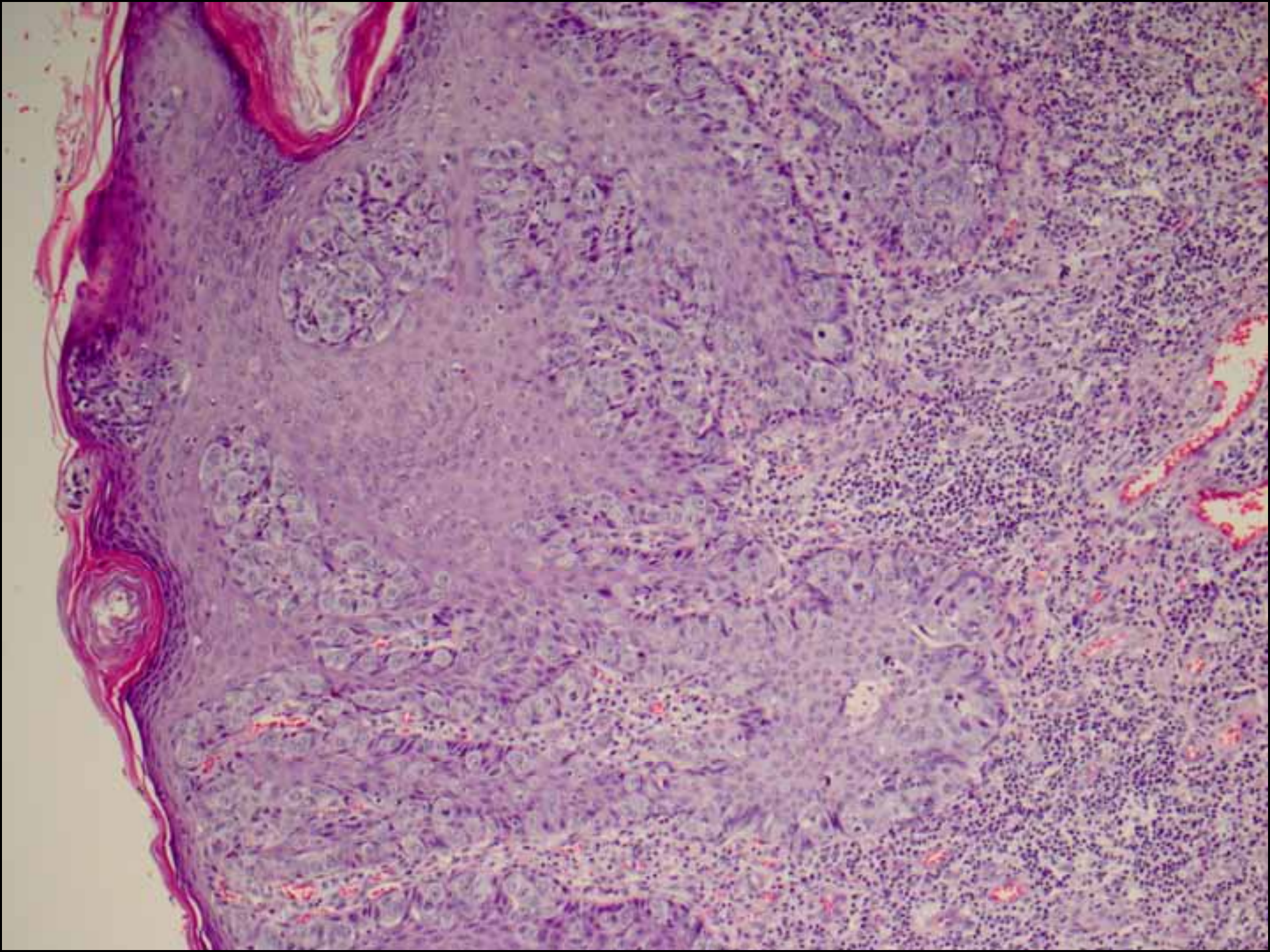
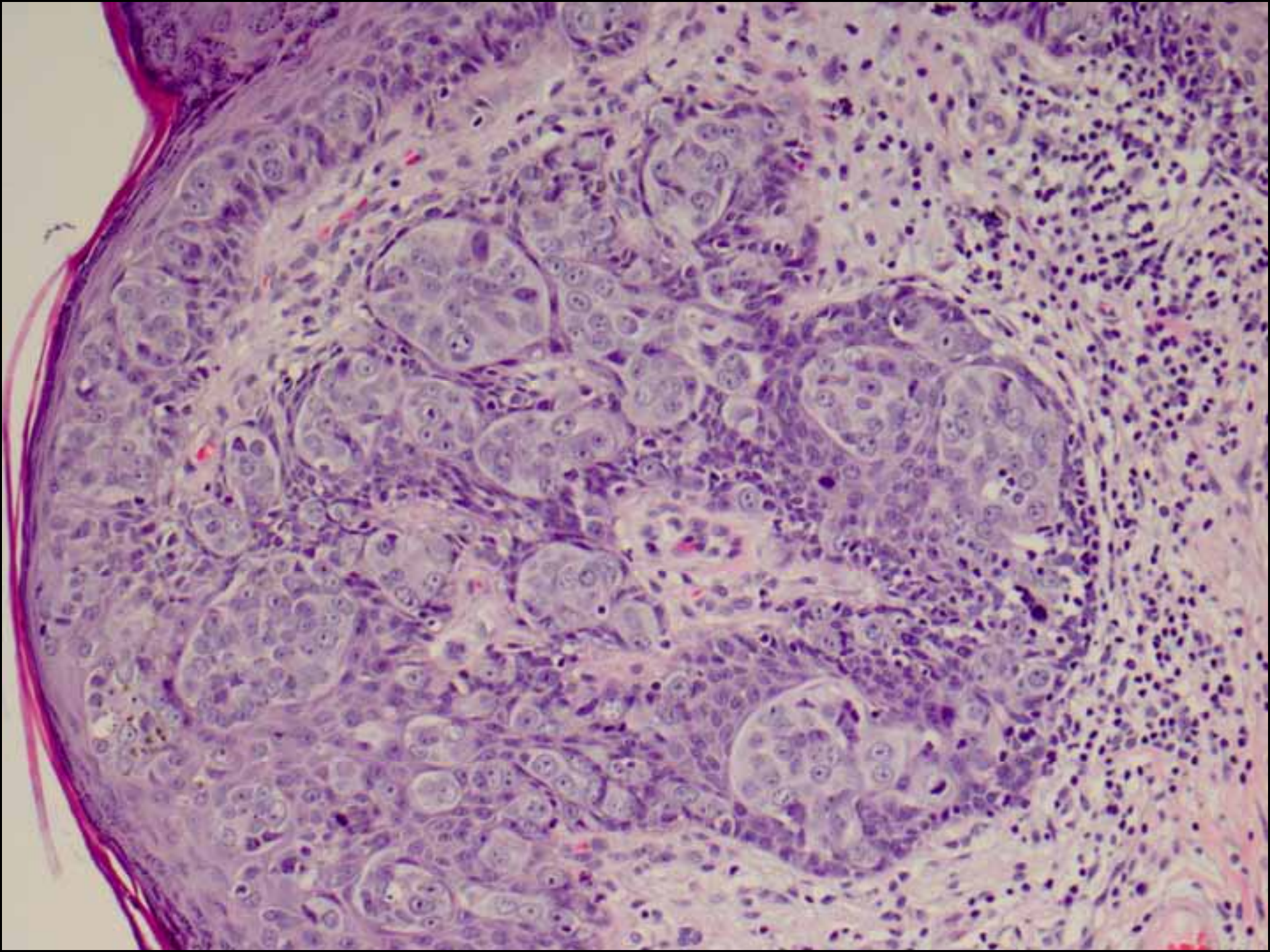


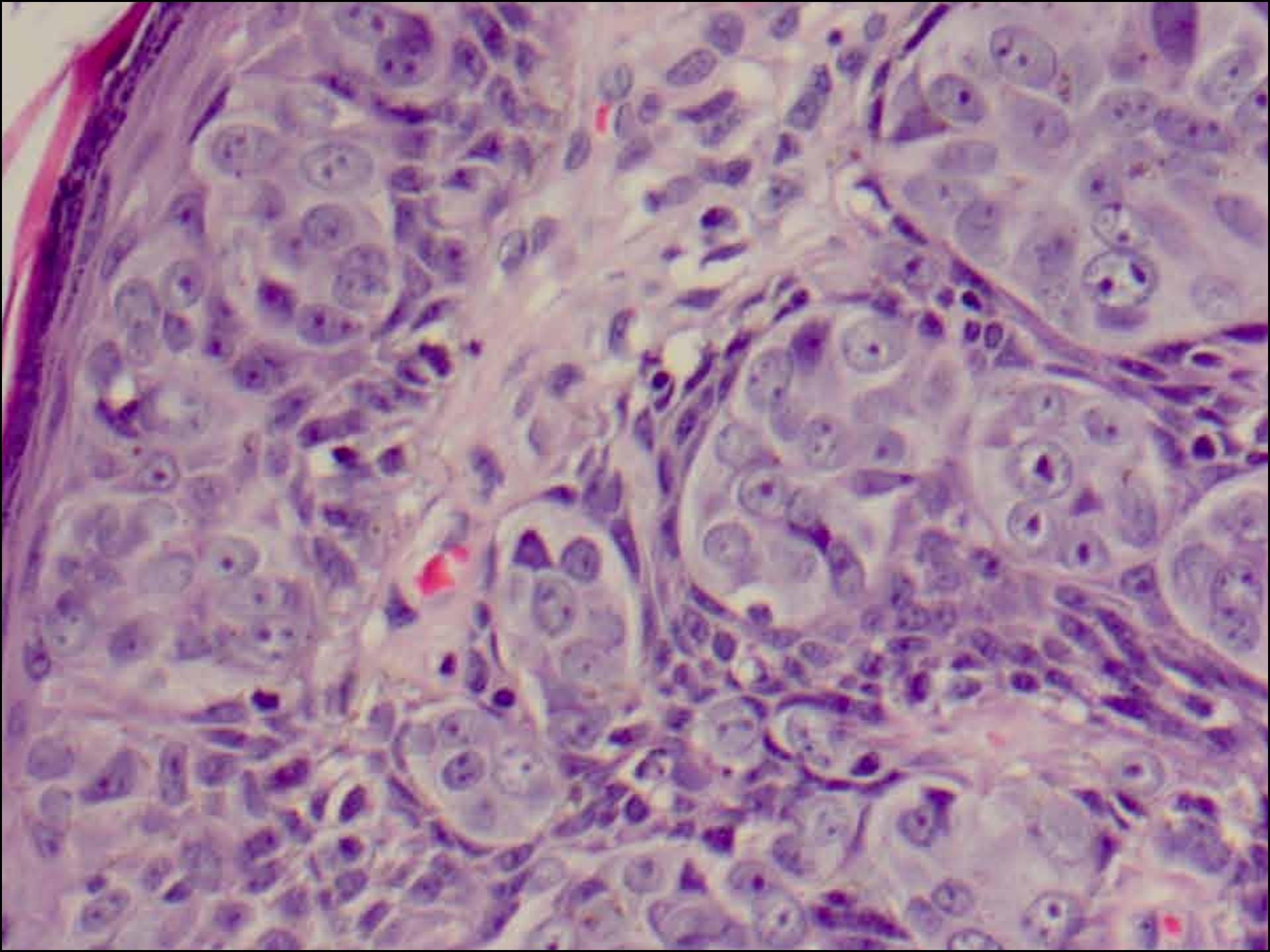
76 year old Asian male with history of rectal adenocarcinoma presents with right scrotal mass times few months. Mass is small and fungating. The tumor is resected.











CK20

