

LASOP Residents' Night

Jennifer Cotter MSIV

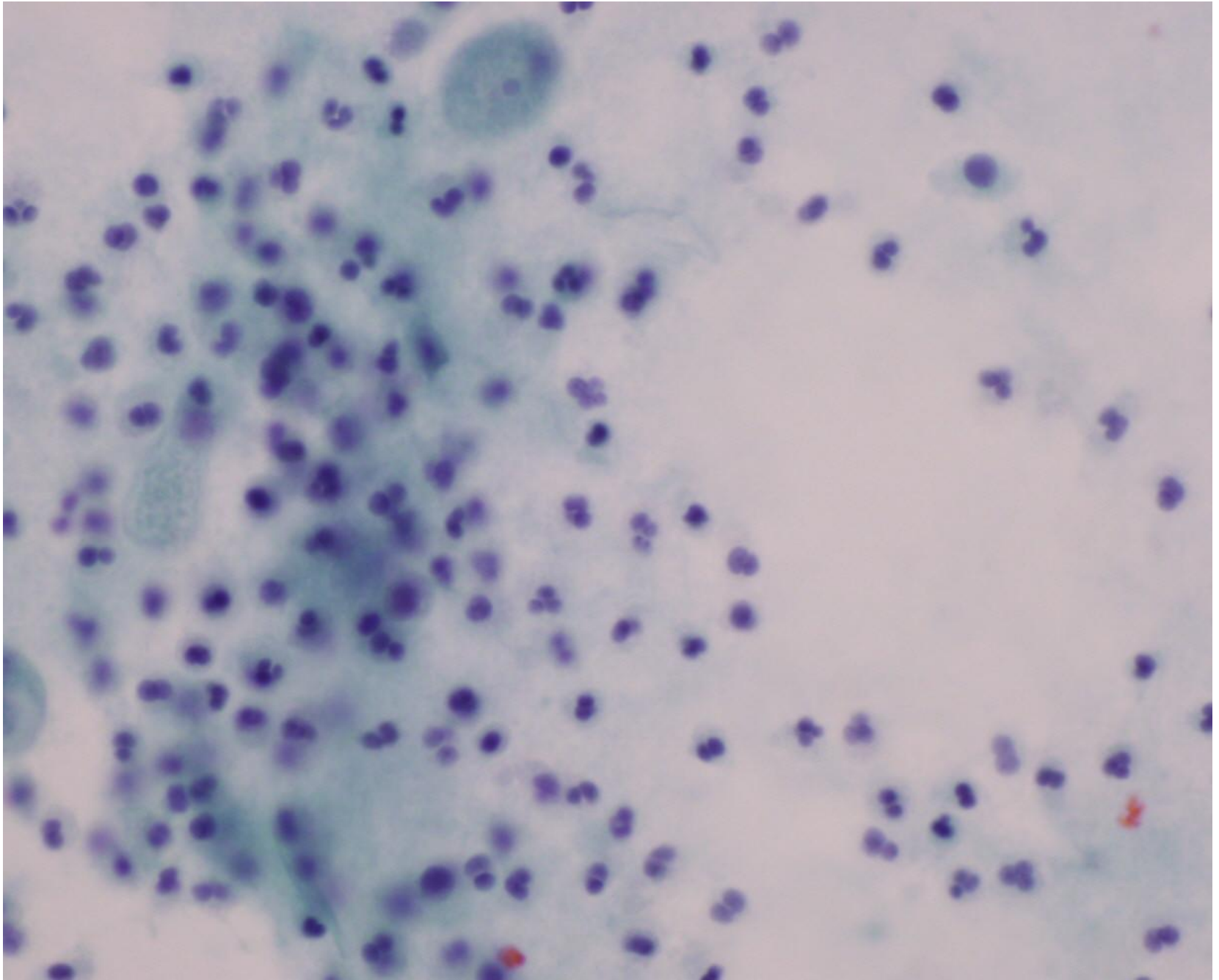
Keck School of Medicine of USC



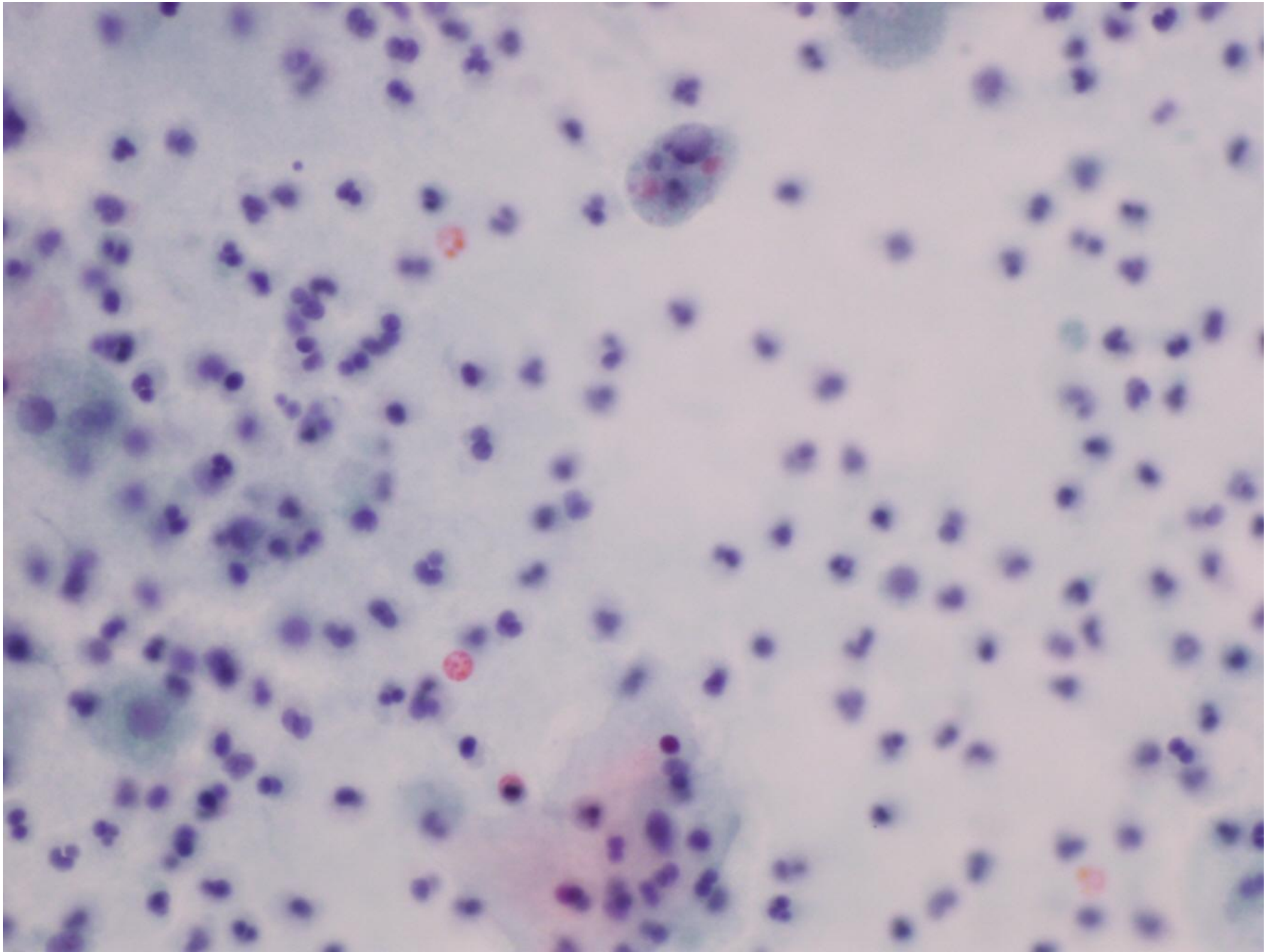
Patient history and symptoms

- **56 year old Hispanic female**
- Past medical history of atrial fibrillation and hypertension, s/p mitral valve replacement with mechanical ball valve 26 years ago, on anticoagulation
- Presents to emergency department complaining of **gross hematuria** and sensation of “ball” in right groin
- Reports history of “on and off” **hematuria for one year**, has been treated with trimethoprim-sulfamethoxazole for positive **E.coli** urine culture with test of cure showing no evidence of infection
- In emergency department, pelvic ultrasound shows **3.5 cm mass of bladder wall**, voided urine cytology sent
- CT shows mass, mixed enhancement, up to 32mm diameter, no adenopathy
- Cystoscopy shows diffuse hyperemia and large right posterolateral mass

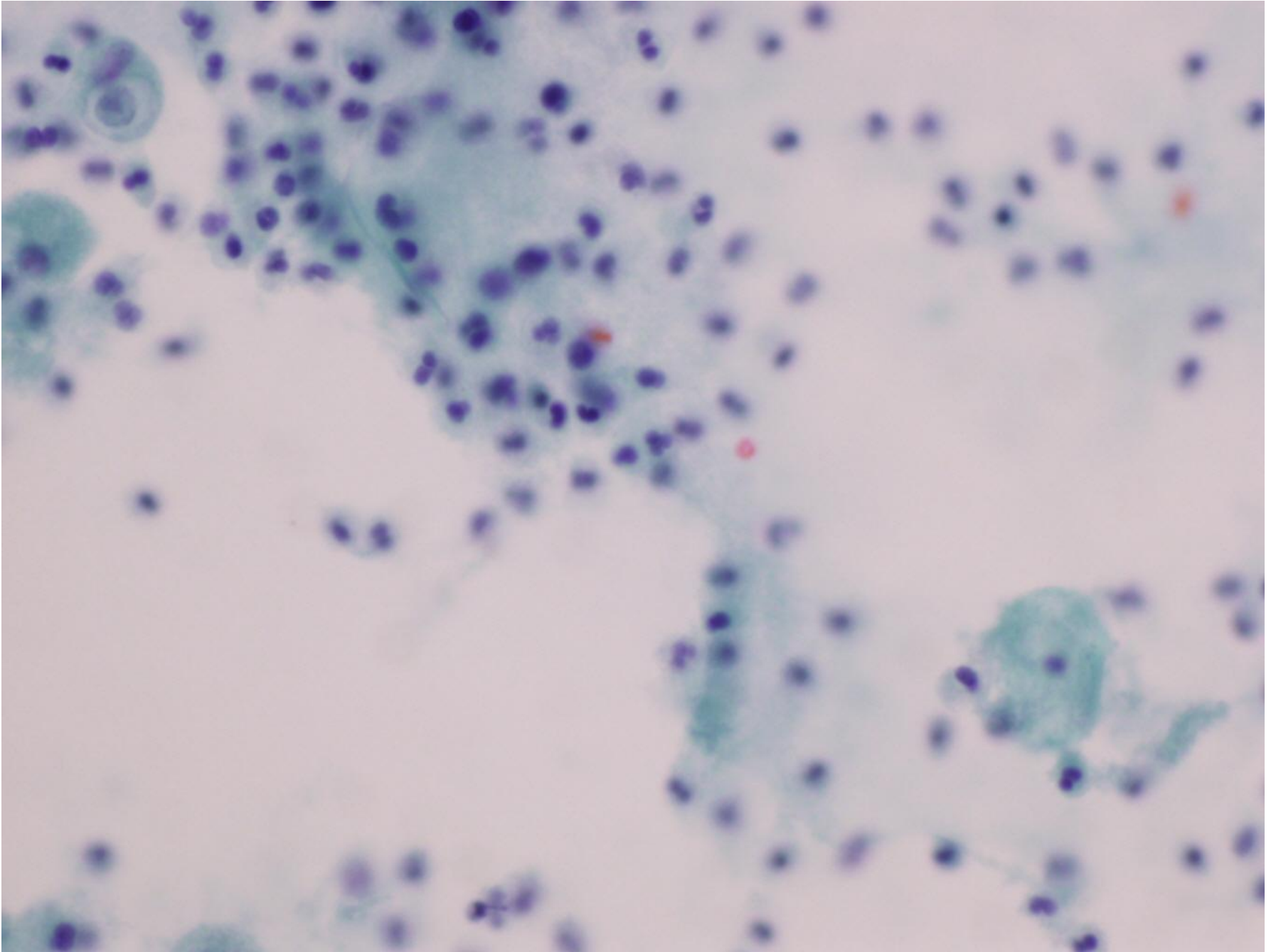
Voided urine



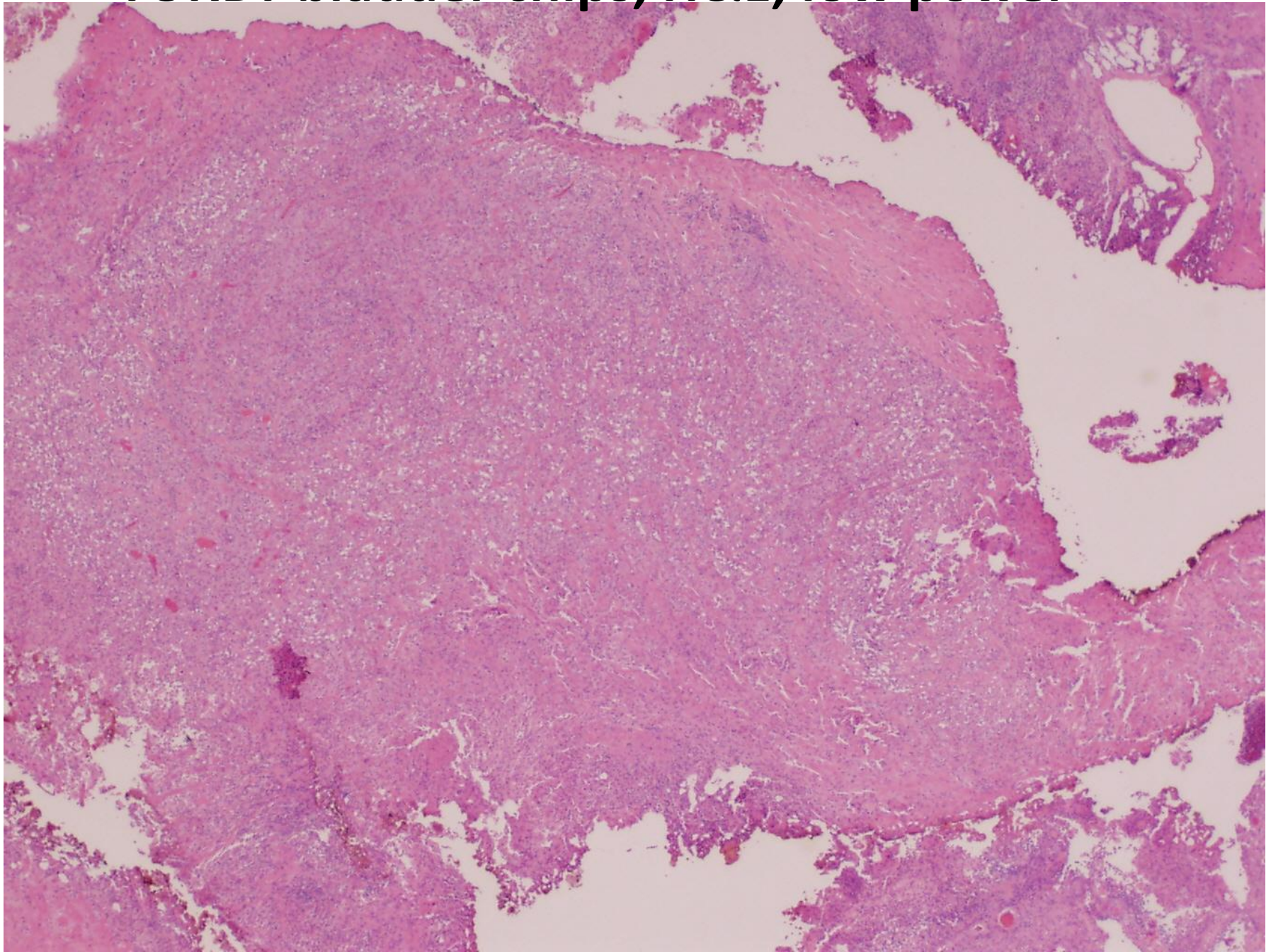
Voided urine



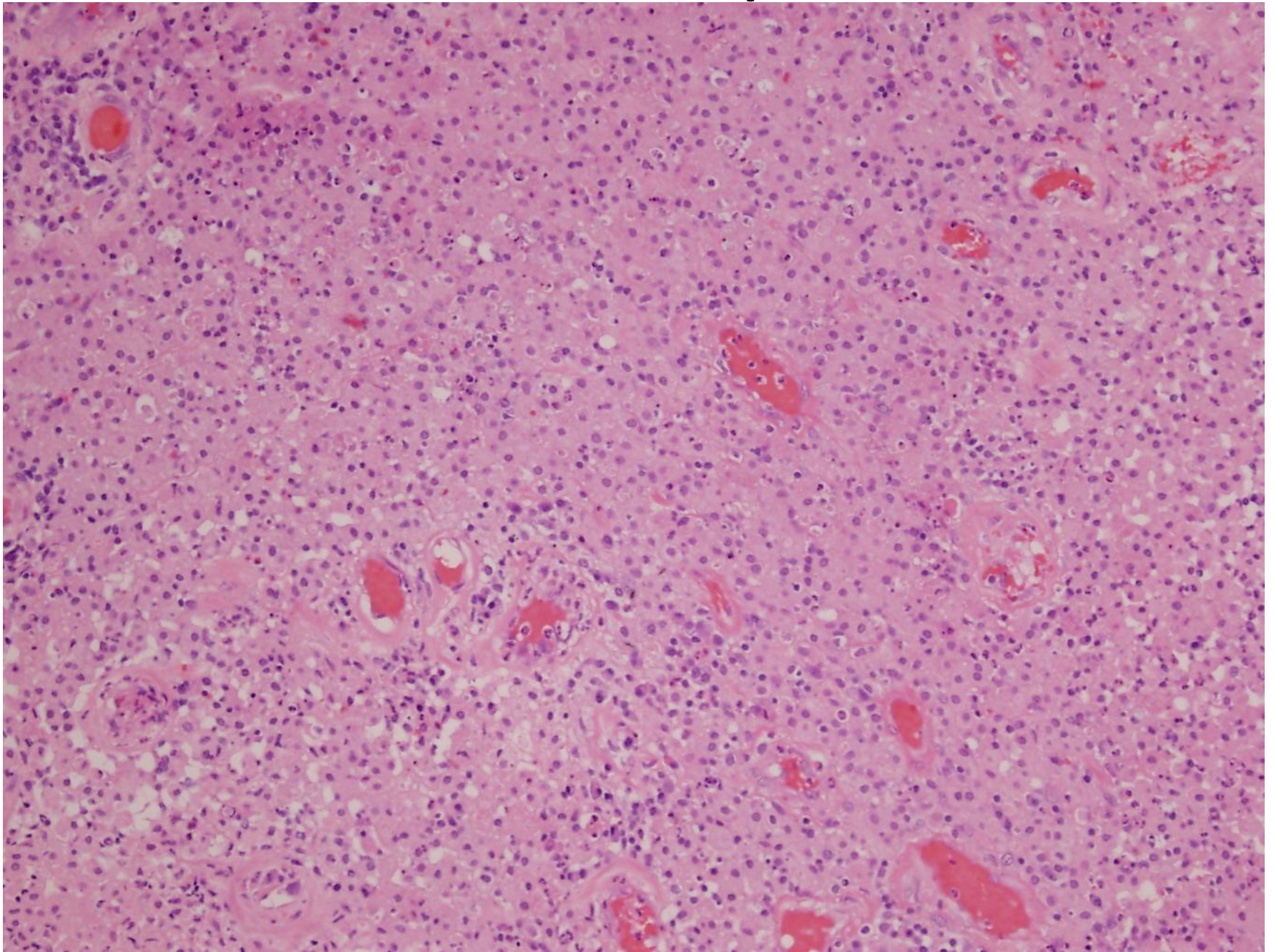
Voided urine



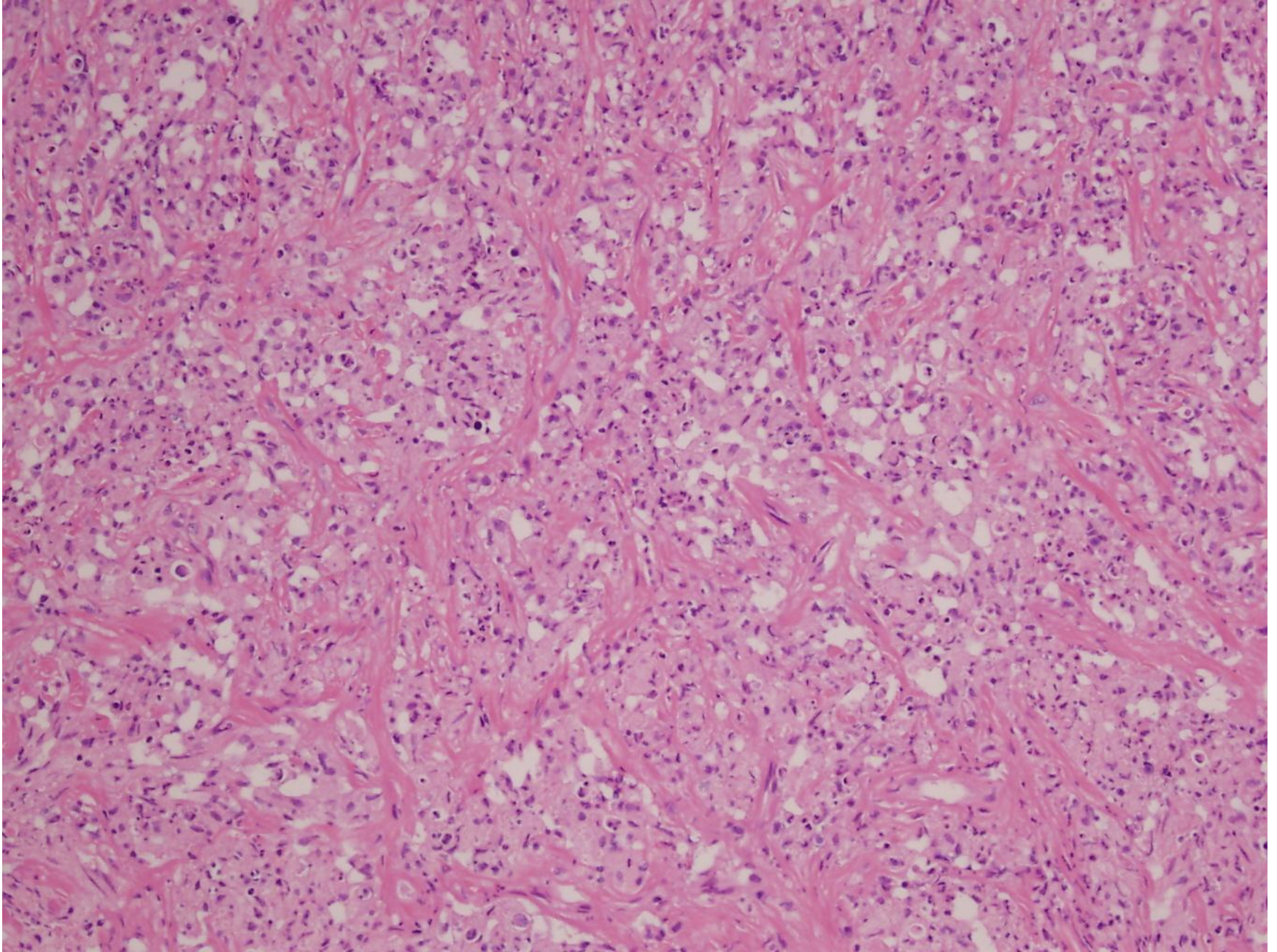
TURBT bladder chips, H&E, low power



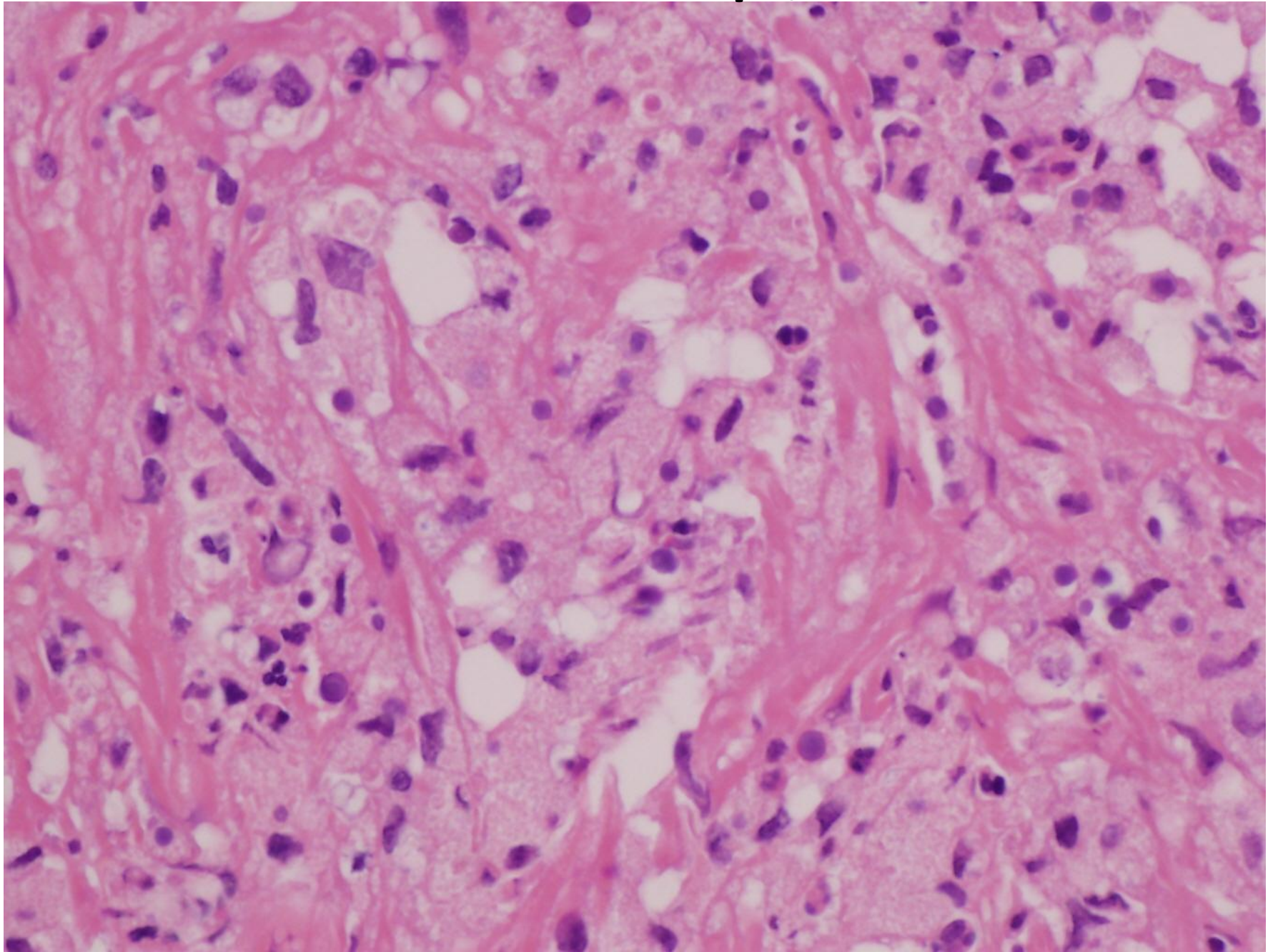
TURBT bladder chips, H&E



TURBT bladder chips, H&E



TURBT bladder chips, H&E



TURBT bladder chips, H&E

