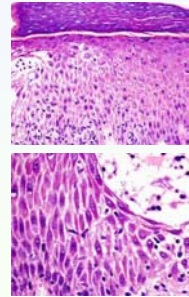


Spongiosis and Spongiotic Dermatitis

G.Peter Sarantopoulos, MD
UCLA Medical Center

Spongiosis

- What is 'spongiosis'?
 - Intra-epidermal and intercellular edema
 - Widening of intercellular spaces between keratinocytes
 - Elongation of intercellular bridges



Spongiosis

- 'Spongiosis' as a histologic concept (not a diagnosis!)
 - Intra-epidermal edema accompanies many (if not all) inflammatory skin diseases to some degree
- Important to distinguish spongiosis as...
 - The *predominant* histologic finding
 - A non-specific feature of *other* inflammatory dermatoses (e.g. lichenoid/interface, vasculopathic, psoriasiform, etc)
 - Sometimes, there is overlap

Spongiosis vs. Spongiotic Dermatitis

- Not everything 'spongiotic' is a spongiotic dermatitis
- So-called 'patterns of spongiosis'
 - Neutrophilic
 - Eosinophilic
 - Follicular
 - Miliarial

Dermatitis with 'Spongiosis'

Neutrophilic:

Pustular psoriasis
Reiter's syndrome
IgA Pemphigus
Pemphigus herpetiformis
Infantile acropustulosis
AGEP
Palmoplantar pustulosis
SSSS
Neisserial infections
Dermatophytoses
Candidosis
Beetle dermatitis (Paederus)
Pustular contact dermatitis

Eosinophilic:

Pemphigus (precursor)
Pemphigus vegetans
Bullous pemphigoid
Cicatrical pemphigoid
Pemphigoid (herpes) gestationis
Idiopathic eosinophilic spongiosis
Allergic contact dermatitis
Atopic dermatitis
Arthropod dermatitis
Ofuji's Disease
Incontinentia pigmenti
Drug reactions
Autoeczematization ('Id')

Miliarial:

M. Crystallina
M. Rubra
M. profunda

Follicular:

Infundibulofolliculitis
Atopic dermatitis (follicular lesions)
Apocrine miliaria
Eosinophilic folliculitis

Dermatitis with 'Spongiosis' *

Neutrophilic:

Pustular psoriasis
Reiter's syndrome
IgA Pemphigus
Pemphigus herpetiformis
Infantile acropustulosis
AGEP
Palmoplantar pustulosis
SSSS
Neisserial infections
Dermatophytoses
Candidosis
Beetle dermatitis (Paederus)
Pustular contact dermatitis

Eosinophilic:

Pemphigus (precursor)
Pemphigus vegetans
Bullous pemphigoid
Cicatrical pemphigoid
Pemphigoid (herpes) gestationis
Idiopathic eosinophilic spongiosis
Allergic contact dermatitis
Atopic dermatitis
Arthropod dermatitis
Ofuji's Disease
Incontinentia pigmenti
Drug reactions
Autoeczematization ('Id')

Miliarial:

M. Crystallina
M. Rubra
M. profunda

Follicular:

Infundibulofolliculitis
Atopic dermatitis (follicular lesions)
Apocrine miliaria
Eosinophilic folliculitis

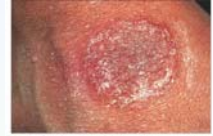* Some overlap exists between what Dermatopathologists consider 'spongiotic dermatitis' and so-called patterns of spongiosis

Spongiotic Dermatitis

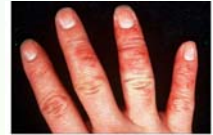- Select entities commonly encountered in daily practice
 - Nummular eczema
 - Contact dermatitis
 - Seborrheic dermatitis
 - Pityriasis rosea

Spongiotic Dermatitis

- Nummular eczema
 - Clinical:
 - Tiny papules / papulovesicles, may coalesce to form coin-shaped patches, single or multiple
 - Dorsum of hands, extensor forearms, lower legs / outer thigh, posterior trunk



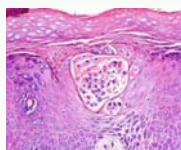
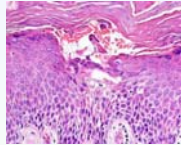
© Elsevier Ltd 2005. McKuz et al. Pathology of the Skin with Clinical Correlations, 3e



© Elsevier Ltd 2005. McKuz et al. Pathology of the Skin with Clinical Correlations, 3e

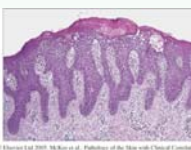
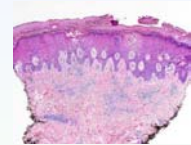
Spongiotic Dermatitis

- Nummular eczema
 - *Early lesions* – spongiosis leading to vesiculation, vesicles often contain inflammatory cells (may mimic Pautrier's microabscesses!)
 - *Later lesions* – progressive psoriasiform hyperplasia (less regular than allergic CD!)



Spongiotic Dermatitis

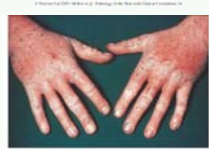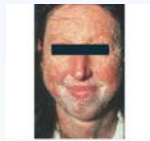- Nummular eczema
 - *Early lesions* – spongiosis leading to vesiculation, vesicles often contain inflammatory cells (may mimic Pautrier's microabscesses!)
 - *Later lesions* – progressive psoriasiform hyperplasia



© Elsevier Ltd 2005. McKuz et al. Pathology of the Skin with Clinical Correlations, 3e

Spongiotic Dermatitis

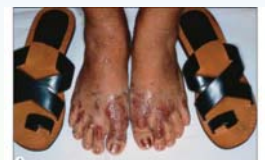- Contact Dermatitis
 - Clinical: *Irritant CD*
 - Reactions vary – simple erythema to purpura to eczematous to vesiculobullous reactions
 - Identified at sites of exposure



© Elsevier Ltd 2005. McKuz et al. Pathology of the Skin with Clinical Correlations, 3e

Spongiotic Dermatitis

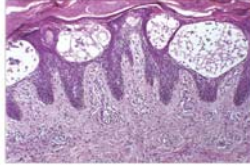
- Contact Dermatitis
 - Clinical: *Allergic CD*
 - Erythematous papules, small vesicles or weeping plaques
 - Lesions arise 12-48 hrs following exposure to allergen, lesions often extend beyond site of exposure



© 2003 Elsevier - Biologia, Britton and Rapini: Dermatology - www.dermnet.com

Spongiotic Dermatitis

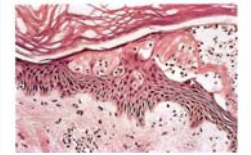
- Contact Dermatitis
 - Spongiosis leads to **intraepidermal vesicles**
 - '**Irritant**' often more marked changes, ballooning / necrosis, possible **neuts**; varies with irritant concentration
 - '**Allergic**'; spongiosis often with **eos**, persistent lesions often show scale crust with regular psoriasiform hyperplasia



© Elsevier Ltd 2005. McKee et al., Pathology of the Skin with Clinical Correlations, 3e

Spongiotic Dermatitis

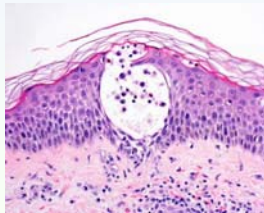
- Contact Dermatitis
 - Spongiosis leads to intraepidermal vesicles
 - '**Irritant**' often more marked changes, ballooning/necrosis, possible **neuts**; varies with irritant concentration
 - '**Allergic**'; spongiosis often with **eos**, persistent lesions often show scale crust with regular psoriasiform hyperplasia



© Weedon, Skin Pathology, 2002

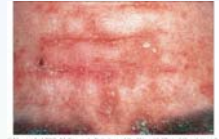Spongiotic Dermatitis

- Contact Dermatitis
 - Spongiosis leads to intraepidermal vesicles
 - '**Irritant**' often more marked changes, ballooning/necrosis, possible **neuts**; varies with irritant concentration
 - '**Allergic**'; spongiosis often with **eos**, persistent lesions often show scale crust with regular psoriasiform hyperplasia

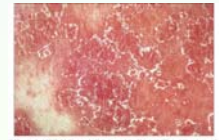


Spongiotic Dermatitis

- Seborrheic dermatitis
 - Clinical:
 - Erythematous, scaling papules and plaques, sometimes with a greasy appearance
 - Found upon 'seborrheic' areas – scalp, ears, eyebrows, eyelid margins, nasolabial areas
 - Males, after puberty; common manifestation in AIDS



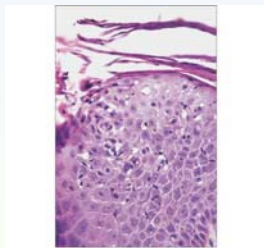
© Elsevier Ltd 2005. McKee et al., Pathology of the Skin with Clinical Correlations, 3e



© Elsevier Ltd 2005. McKee et al., Pathology of the Skin with Clinical Correlations, 3e

Spongiotic Dermatitis

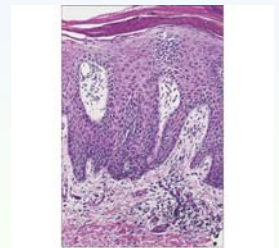
- Seborrheic dermatitis
 - **Acute / subacute** - spongiosis with scale crust
 - **Later** – psoriasiform epidermal hyperplasia
 - Lymphocytes, macrophages, occasional neuts upon a mildly edematous superficial papillary dermis
 - **Note:** folliculocentric scale crust **favors SD** over psoriasis



© Elsevier Ltd 2005. McKee et al., Pathology of the Skin with Clinical Correlations, 3e

Spongiotic Dermatitis

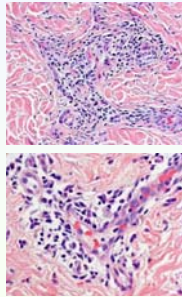
- Seborrheic dermatitis
 - **Acute/subacute** - spongiosis with scale crust
 - **Later** – psoriasiform epidermal hyperplasia
 - Lymphocytes, macrophages, occasional neuts upon a mildly edematous superficial papillary dermis
 - **Note:** folliculocentric scale crust **favors SD** over psoriasis



© Elsevier Ltd 2005. McKee et al., Pathology of the Skin with Clinical Correlations, 3e

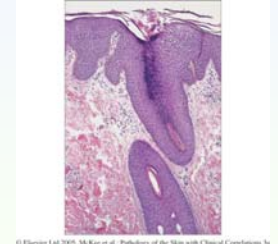Spongiotic Dermatitis

- Seborrheic dermatitis
 - *Acute/subacute* - spongiosis with scale crust
 - *Later* – psoriasiform epidermal hyperplasia
 - Lymphocytes, macrophages, occasional neutrophils upon a mildly edematous superficial papillary dermis
 - *Note*: folliculocentric scale crust favors SD over psoriasis



Spongiotic Dermatitis

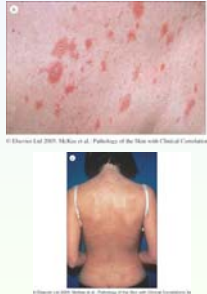- Seborrheic dermatitis
 - *Acute/subacute* - spongiosis with scale crust
 - *Later* – psoriasiform epidermal hyperplasia
 - Lymphocytes, macrophages, occasional neutrophils upon a mildly edematous superficial papillary dermis
 - *Note*: folliculocentric scale crust favors SD over psoriasis



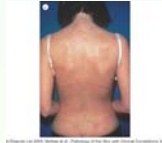© Elsevier Ltd 2005. McKuz et al. Pathology of the Skin with Clinical Correlations, 3e

Spongiotic Dermatitis

- Pityriasis Rosea
 - Clinical:
 - Oval, salmon-pink lesions; initial scaly plaque 'herald patch' often
 - Trunk, neck, proximal extremities; follow lines of cleavage
 - All ages; often 10 – 35 yo



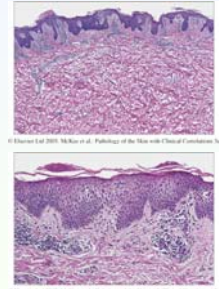
© Elsevier Ltd 2005. McKuz et al. Pathology of the Skin with Clinical Correlations, 3e



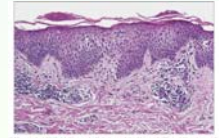
© Elsevier Ltd 2005. McKuz et al. Pathology of the Skin with Clinical Correlations, 3e

Spongiotic Dermatitis

- Pityriasis Rosea
 - Vaguely undulating epidermis, 'mounded' parakeratosis, usually lessened granular layer
 - Focal spongiosis leads to small vesicles, dyskeratotic cells seen at all levels of epidermis (> in 'herald patch')
 - Pigment incontinence, superficial pap-derm edema, rbc extrav, mild-mod lymph inflammation with macrophages



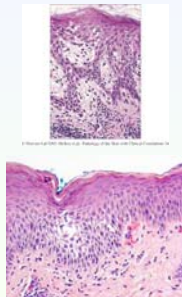
© Elsevier Ltd 2005. McKuz et al. Pathology of the Skin with Clinical Correlations, 3e



© Elsevier Ltd 2005. McKuz et al. Pathology of the Skin with Clinical Correlations, 3e

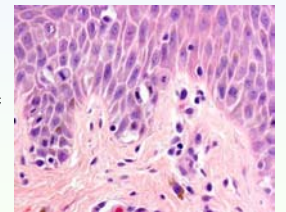
Spongiotic Dermatitis

- Pityriasis Rosea
 - Vaguely undulating epidermis, 'mounded' parakeratosis, usually lessened granular layer
 - Focal spongiosis leads to small vesicles, dyskeratotic cells seen at all levels of epidermis (> in 'herald patch')
 - Pigment incontinence, superficial pap-derm edema, rbc extrav, mild-mod lymph inflammation with macrophages



Spongiotic Dermatitis

- Pityriasis Rosea
 - Vaguely undulating epidermis, 'mounded' parakeratosis, usually lessened granular layer
 - Focal spongiosis leads to small vesicles, dyskeratotic cells seen at all levels of epidermis (> in 'herald patch')
 - Pigment incontinence, superficial pap-derm edema, rbc extrav, mild-mod lymph inflammation with macrophages



Spongiotic Dermatitis

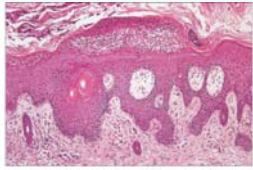
- Pityriasis rosea
 - Neuts within parakeratotic mounds *favors psoriasis*
 - Mounded parakeratosis favors PR (*over acute/subacute eczema*)
 - *Always consider drugs* - wide range of drugs may show a PR-like eruption

Spongiotic Dermatitis

- Don't be fooled - spongiosis in and of itself is a non-specific finding – pitfall!
- Spongiosis may be identified as a part of any number of inflammatory skin disorders
- Look for the predominant reaction pattern
- Examples of overlap...

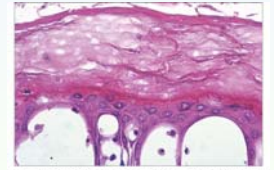
Don't Be Fooled!

- **Infectious –**
 - **Fungal infections** (dermatophytoses) often mimic the histologic features of *psoriasis*
 - Some infections may show marked *spongiosis* as well – even forming marked vesiculation
 - A PAS with diastase stain can quickly lead you to the diagnosis and save the patient additional time and morbidity



© Elsevier Ltd 2005. McKee et al., Pathology of the Skin with Clinical Correlations 3e

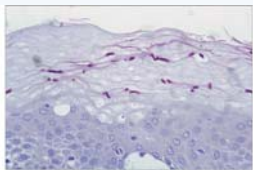
- **Infectious –**
 - **Fungal infections** (dermatophytoses) often mimic the histologic features of *psoriasis*
 - Some infections may show marked *spongiosis* as well – even forming marked vesiculation
 - A PAS with diastase stain can quickly lead you to the diagnosis and save the patient additional time and morbidity



© Elsevier Ltd 2005. McKee et al., Pathology of the Skin with Clinical Correlations 3e

Don't Be Fooled!

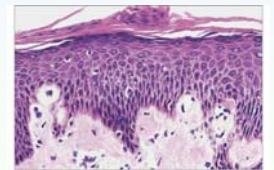
- **Infectious –**
 - **Fungal infections** (dermatophytoses) often mimic the histologic features of *psoriasis*
 - Some infections may show marked *spongiosis* as well – even forming marked vesiculation
 - A PAS with diastase stain can quickly lead you to the diagnosis and save the patient additional time and morbidity



© Elsevier Ltd 2005. McKee et al., Pathology of the Skin with Clinical Correlations 3e

Don't Be Fooled!

- **Psoriasiform**
 - **Psoriasis, early psoriasis** may show *spongiosis* associated with lymphocyte exocytosis
 - **Established psoriasis** seen on the palms and soles may show *spongiosis* – making a distinction from *allergic contact dermatitis* difficult
 - **Erythrodermic psoriasis** may also show *spongiosis*

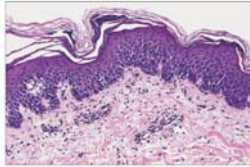


© Elsevier Ltd 2005. McKee et al., Pathology of the Skin with Clinical Correlations 3e

Don't Be Fooled!

• Psoriasiform

- Psoriasis, early psoriasis may show *spongiosis* associated with lymphocyte exocytosis
- *Established psoriasis* seen on the palms and soles may show *spongiosis* – making a distinction from *allergic contact dermatitis* difficult
- *Erythrodermic psoriasis* may also show *spongiosis*

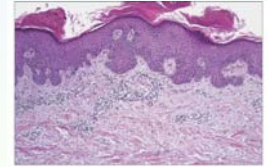


© Elsevier Ltd 2005. McKee et al., Pathology of the Skin with Clinical Correlations 3e

Don't Be Fooled!

• Psoriasiform

- Psoriasis, early psoriasis may show *spongiosis* associated with lymphocyte exocytosis
- *Established psoriasis* seen on the palms and soles may show *spongiosis* – making a distinction from *allergic contact dermatitis* difficult
- *Erythrodermic psoriasis* may also show *spongiosis*

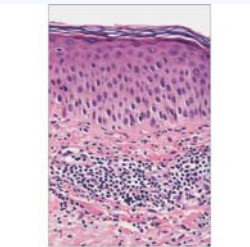


© Elsevier Ltd 2005. McKee et al., Pathology of the Skin with Clinical Correlations 3e

Don't Be Fooled!

• Vasculopathic

- Erythema annulare centrifugum (EAC), characteristic annular, erythematous lesion may show a fine scale inside the advancing edge
- Histology shows *spongiosis*, *parakeratosis* and an underlying superficial perivascular lymphocytic inflammation, often with a 'coat-sleeve' appearance

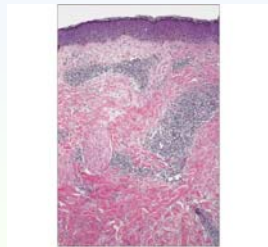


© Elsevier Ltd 2005. McKee et al., Pathology of the Skin with Clinical Correlations 3e

Don't Be Fooled!

• Vasculopathic

- Erythema annulare centrifugum (EAC), characteristic annular, erythematous lesion may show a fine scale inside the advancing edge
- Histology shows *spongiosis*, *parakeratosis* and an underlying superficial perivascular lymphocytic inflammation, often with a 'coat-sleeve' appearance

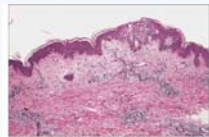


© Elsevier Ltd 2005. McKee et al., Pathology of the Skin with Clinical Correlations 3e

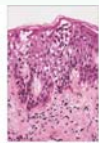Spongiotic Dermatitis

• Vasculopathic

- Pruritic urticarial papules and plaques of pregnancy (PUPPP), aka polymorphic eruption of pregnancy
- Epidermal changes, to include *spongiosis* and *parakeratosis* with exocytosis of inflammatory cells may be seen in up to 1/3 of cases
- Lymphocytic vasculitis with varying admixture of eosinophils and variable edema of the superficial papillary dermis



© Elsevier Ltd 2005. McKee et al., Pathology of the Skin with Clinical Correlations 3e

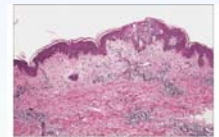


© Elsevier Ltd 2005. McKee et al., Pathology of the Skin with Clinical Correlations 3e

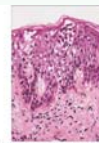
Spongiotic Dermatitis

• Vasculopathic

- Pruritic urticarial papules and plaques of pregnancy (PUPPP), aka polymorphic eruption of pregnancy
- Epidermal changes, to include *spongiosis* and *parakeratosis* with exocytosis of inflammatory cells may be seen in up to 1/3 of cases
- Lymphocytic vasculitis with varying admixture of eosinophils and variable edema of the superficial papillary dermis



© Elsevier Ltd 2005. McKee et al., Pathology of the Skin with Clinical Correlations 3e

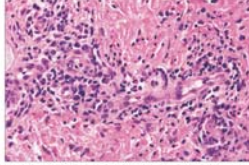


© Elsevier Ltd 2005. McKee et al., Pathology of the Skin with Clinical Correlations 3e

Spongiotic Dermatitis

- **Vasculopathic**

- Pruritic urticarial papules and plaques of pregnancy (PUPPP), aka polymorphic eruption of pregnancy
- Epidermal changes, to include *spongiosis* and parakeratosis with exocytosis of inflammatory cells may be seen in up to 1/3 of cases
- Lymphocytic vasculitis with varying admixture of eosinophils and variable edema of the superficial papillary dermis

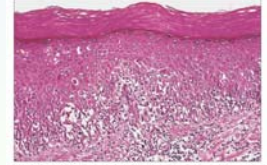


© Elsevier Ltd 2005. McKee et al., Pathology of the Skin with Clinical Correlations 34

Spongiotic Dermatitis

- **Interface/lichenoid**

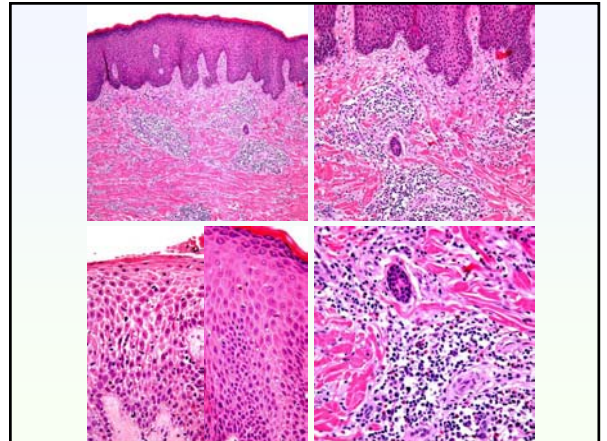
- Erythema multiforme, early lesions may show intra- and intercellular intraepidermal edema (*spongiosis*)



© Elsevier Ltd 2005. McKee et al., Pathology of the Skin with Clinical Correlations 34

Clinical History

- 54 yo woman is seen by her Dermatologist complaining of an itching, burning rash
- Physical exam showed a morbilliform rash on the lower extremities and trunk
- Further questioning revealed that the patient had recently changed one of her blood pressure medications



Drug Eruption

- Drug eruptions are one of the more commonly biopsied inflammatory skin lesions
 - Drug eruptions may show a wide range of histologic patterns
 - Spongiosis with eosinophils is a common pattern
- Any number of medications may incite a rash

Sources

Weedon, Skin Pathology. Churchill Livingstone, 2002
McKee, Pathology of the Skin, Elsevier-Mosby, 2005
Additional micrographs from personal collection

Questions/comments: gsarantopoulos@mednet.ucla.edu